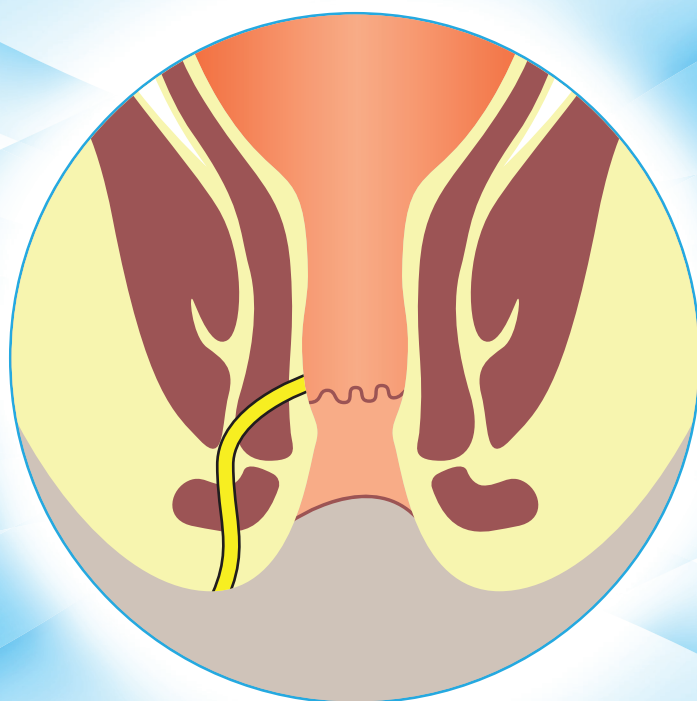




The Association of Colon and Rectal Surgeons of India

(A Section of ASI)



FISTULA IN ANO

PRACTICE GUIDELINES 2021



The Association Of Colon And Rectal Surgeons Of India

Practice Parameters Consensus Meeting - 11th Nov 2021, Hotel Renaissance Mumbai

SITTING - (Left to Right) - Roy V Patankar, Mrs Kumkum Singh, Kushal Mital, Niranjan Agarwal, Parvez Sheikh, Pradeep P Sharma, Nisar A Chowdri

STANDING 1st ROW (Left to Right) - Rajashekar Mohan, Pravin P. Gore, Fazlul Qadir Parray, Tamonas Chaudhuri, R Kannan, Ajit Naniksingh Kukreja, Arshad Ahmad, M Kanagavel

DING 2nd ROW (Left to Right) - Kamal Gupta, C P Kothari, Ashok Kumar, Atul Deshpande, Ajay K Khanna, Bhanwar Lal Yadav, Prajesh Bhuta, Avanish Saklani, Shekhar Suradkar

List of Contributors

Parvez Sheikh

MS, FACRSI
Head – Department of Colorectal Surgery
Saifee Hospital,
Mumbai, Maharashtra, India

Niranjan Agarwal

MS DNB FACRSI
Consultant Surgeon Bombay Hospital
Mumbai
Chief Surgeon Salasar Nursing Home
Bhayndar (Thane)

Arshad Ahmad

MS FICS FMAS FIAGES FLCS
Professor, Department of Surgery
King George's Medical University
Lucknow, UP, India

Clinical Practice Guidelines Committee

Ajay K Khanna
Ajit Naniksingh Kukreja
Ashok Kumar
Ashok Ladha
Atul Deshpande
Avanish Saklani
Bhanwar Lal Yadav
Brij B. Agarwal
C P Kothari
Deepak Govil
Fazlul Qadir Parray
K.S. Mayilvaganan
Kamal Gupta
Kushal Mital
M Kanagavel
Mrs Kumkum Singh
Mrs Shalu Gupta
Nisar A Chowdri
Pradeep P Sharma
Prajeshe Bhuta
Pravin P. Gore
R Kannan
Rajashekar Mohan
Roy V Patankar
Shekhar Suradkar
Tamonas Chaudhuri
Varughese Mathai
Venkatesh Munikrishnan

Acknowledgments: The authors would like to acknowledge CBCC Global Research for their writing and editorial support in the development of ACRSI Fistula in ano guidelines.

Foreword

Disorders of the colon and rectum are not only very common but complex too and many a time difficult to treat. The urge to provide best treatment amongst the vast majority available is even more perplexing and frustrating at times. This gets further compounded by the lack of supporting evidences locally. Our members are more guided by evidences produced by other part of the world though it is a well known fact that colorectal disorder occurrences, behaviour and treatment responses may differ across the continents. A need was therefore felt to compile various available literature for some common colorectal disorders and produce them in the form of Practice Guidelines suitable for our members. It is an established fact that treatment modalities guided by the explicit, careful and judicious use of the best evidence available serves as a guide for most appropriate clinical decision making and patient care.

The Association of Colon and Rectal Surgeons of India lead by its team of expert faculties in their respective fields have done some excellent literature search and collated the available experiences to prepare this guidelines for you. We hope this will serve as a ready reckoner for our members in their times of need and help them to combat many litigations too.

I take this opportunity to thank all the contributors for their constant support in this endeavour.

Dr. Niranjan Agarwal
President-ACRSI

Disclaimer: This document is not a substitute for proper training, experience, and exercising of professional judgment. While every effort has been made to ensure the accuracy of the contents at the time of publication, neither the authors nor the ACRSI give any guarantee as to the accuracy of the information contained in them nor accept any liability, with respect to loss, damage, injury or expense arising from any such errors or omissions in the contents of the work

For the use only of a Registered Medical Practitioner or a Hospital or a Laboratory only
These Guidelines on Fistula in Ano have been developed independently by The Association Of Colon & Rectal Surgeons Of India (ACRSI) with the support of Abbott India Limited

National Executive Committee (2019-2021)

PRESIDENT

Niranjan Agarwal (Mumbai)

PRESIDENT ELECT

Nisar Chowdri (Srinagar)

HON. SECRETARY

Kushal Mital (Thane)

VICE PRESIDENTS

Arshad Ahmad (Lucknow)
Prajesh Bhuta (Mumbai)
Tamonas Chaudhari (Kolkata)
Mukesh Srivastava (Jabalpur)
Rajashekar Mohan (Mangalore)

EXECUTIVE MEMBERS

Deepak Govil (Delhi)
Atul Deshpande (Aurangabad)
C. P. Kothari (Indore)
R Kannan (Chennai)
Sukumar Maiti (West Bengal)

CO-OPTED MEMBERS

Bhanwar Lal Yadav (Jaipur)
Kamal Gupta (Jalandhar)

IMM. PAST PRESIDENT

Ashok Kumar (Lucknow)

ACADEMIC CONVENOR

Chetan Kantharia (Mumbai)

JT. ACADEMIC CONVENOR

Shalu Gupta (Jaipur)

EDITOR- IJCP

Brij Agarwal (Delhi)

FISTULA IN ANO

PRACTICE GUIDELINES 2021

Summary of recommendations

Assessment and Investigations

- A detailed history and physical examination, including proctoscopy and digital examination, should be performed in all cases of anal fistulas. Symptoms, risk factors, location of internal and external openings, fistula tracts, and presence of infection should be assessed in detail. A note of sphincter integrity and continence should be made in all patients. (Strong recommendation based on very-low-quality evidence, 1C)
- Additional imaging techniques, preferably endoanal ultrasound or magnetic resonance imaging, should be considered in complex fistula patients to guide management. (Strong recommendation based on very-low-quality evidence, 1C)

Anorectal Abscess Management

- Patients with acute anorectal abscess should be treated with incision and drainage at the earliest. (Strong recommendation based on very-low-quality evidence, 1C)
- Simultaneous fistulotomy with incision and drainage of the abscess may be considered in selected patients. (Strong recommendation based on moderate-quality evidence, 1B)
- In the treatment of uncomplicated anorectal abscess, antibiotics have a limited role. (Strong recommendation based on moderate-quality evidence, 1B)
- Antibiotics should be considered in presence of acute anorectal sepsis, immunocompromised patients and in patients with prosthetic heart valves. (Weak recommendation based on low-quality evidence, 2C)

Anal Fistula Management

- Simple anal fistulas may be treated by fistulotomy. It results in a reliable cure with good patient satisfaction. (Strong recommendation based on moderate-quality evidence, 1B)
- Fibrin glue has limited use for treating simple and complex anal fistulas. (Weak recommendation based on moderate-quality evidence, 2B)
- Cutting seton has a limited role in treatment of simple and complex anal fistula. (Weak recommendations based on moderate-quality evidence, 2B).
- Draining seton may be used for the control of anorectal sepsis and in patients with secondary anal fistula (Crohn's, tuberculosis).
- Endorectal advancement flaps may be used in the treatment of complex fistula. (Strong recommendation based on low-quality evidence, 1C)
- The anal fistula plug and glue have limited role in treating anal fistulas. (Weak recommendation based on moderate-quality evidence, 2B)
- Ligation of the intersphincteric fistula tract (LIFT) procedure may be used to treat simple and complex anal fistulas. (Strong recommendation based on moderate-quality evidence, 1B)
- Newer technologies such as video-assisted anal fistula treatment (VAAFT) and application of diode laser may be used for treating complex fistulas by surgeons trained and experienced in using these techniques (Strong recommendation based on very low-quality evidence, 1C)
- Fistulectomy with primary sphincter repair is an effective treatment option for complex fistula or in cases of recurrent fistulas, or in patients with preoperative compromised incontinence (Strong recommendation based on low-quality evidence, 1C)

Introduction

Anal fistula or fistula-in-ano is an abnormal communication between the anal canal and perianal region presenting with serosanguinous discharge, which may also contain pus and fecal matter. Sometimes there may be only an internal opening and no external openings. An ano-rectal abscess is an acute form of the disease, whereas anal fistula is a chronic stage of the disease. An anal fistula is a relatively common anorectal condition encountered in clinical practice. The overall prevalence of anal fistula is approximately 1 to 8 per 10,000 patients and varies from country to country. Data from a United Kingdom primary care database (The Health Improvement Network) shows the prevalence of anal fistula 1.35 per 10,000 patients (1) while the estimated prevalence in Europe is 1.39 per 10,000 patients and 2.1 per 10,000 patients in Japan.(2, 3) The incidence of fistula-in-ano from tertiary care centers in rural parts of India was reported as high as 8.6 per 10,000 patients.(4)

The majority of anal fistulae are primarily resulting from cryptoglandular infection. However, a small number of anal fistulae are secondary to specific diseases like tuberculosis, Crohn's disease, and malignancy. An anal fistula may be simple, involving only the lower portion of the sphincter complex. A high anal fistula is one where a substantial portion of the sphincter complex is violated, and division of these muscles can lead to significant impairment of continence. Complex anal fistula includes a high anal fistula, recurrent fistula, anterior fistula in females, secondary anal fistula, and fistula associated with preexisting incontinence.

The treatment strategies of the two types of anal fistulae are different. There is no single treatment modality that is suitable for all types of anal fistulae. The conventional treatment modalities (fistulotomy/fistulectomy) are still considered to be ideal for simple anal fistulae. However, the treatment of complex anal fistula continues to elude the surgeons. Many new treatment modalities have been introduced in the recent past, and there is a constant influx of innovations. Some of these new treatment

modalities have stood the test of time and have found a place among the standard procedures. However, many techniques are still being evaluated, and evidence is still emerging regarding their efficacy.

We hereby summarize the etiology, diagnosis, and evidence-based treatment strategies in anorectal abscess and anal fistula. We have also reviewed the data on response to treatment and approach to special fistulas associated with specific diseases like tuberculosis, Crohn's disease, and malignancy.

Methodology

An organized literature search was performed in PubMed, the Cochrane database of collected reviews, and Google scholar. Additionally, searches were conducted using resources from regulatory bodies and international societies. The search was restricted to articles and abstracts published in English. Keywords such as "anal fistula," "fistula-in-ano," "anorectal abscess," or "anal fistula" along with (seton OR plug OR glue OR fistulectomy OR fistulotomy OR endorectal advancement flap OR LIFT OR laser OR VAAFT) were included. Meta-analyses and prospective, randomized, controlled trials were given preference in developing this consensus document. The draft document was shared with the expert committee members through email, and a consensus was reached during a consensus meeting over video conferencing.

A method adopted by the American Society of Colon and Rectal Surgeons (ASCRS) was used to derive the quality of evidence, wherein Grade 1 was assigned to strong recommendations, and Grade 2 was assigned to weak recommendations. These recommendations were again categorized based on the level of evidence as A for RCTs without important limitations or overwhelming evidence from observational studies, B for RCTs with important limitations (inconsistent results, methodologic flaws, indirect or imprecise) or exceptionally strong evidence from observational studies, and C for observational studies or case series or a consensus opinion of the expert group (Table 1).(5)

TABLE 1. The GRADE system for grading recommendations

Supporting evidence	Quality of evidence	Grade of recommendation	Quality of evidence
RCTs without important limitations or overwhelming evidence from observational studies	Benefits clearly outweigh risk and burdens or vice versa	1	A
	Benefits closely balanced with risks and burdens	2	A
RCTs with important limitations (inconsistent results, methodologic flaws, indirect, or imprecise) or exceptionally strong evidence from observational studies	Benefits clearly outweigh risk and burdens or vice versa	1	B
	Benefits closely balanced with risks and burdens	2	B
Observational studies or case series or consensus opinion of the panel	Benefits clearly outweigh risk and burdens or vice versa	1	C
	Uncertainty in the estimates of benefits, risks and burden; benefits, risks, and burden may be closely balanced	2	C

Causes

The majority of anorectal abscesses/fistulae are usually the result of cryptoglandular infection. The abscess of cryptoglandular origin is due to occlusion of the anal glands. The abscess can spread in a predictable manner to different spaces around the anal canal. The concept of anal gland infection in the pathogenesis of anorectal abscess and fistula is attributed to Chiari (1878) and Hermann and Desfosses (1880).(6, 7) An abscess of cryptoglandular origin may result in an anal fistula after it is drained. Other causes of a perianal abscess include furunculosis, hidradenitis, herpes, HIV, syphilis, actinomycoses, Crohn's disease, tuberculosis, and complication of anal surgeries. Perianal fistula can develop in 66% to 83% of patients following development of perianal abscess.(8, 9)

All recurrent abscesses require complete evaluation to rule out an underlying fistula. However, even without recurrence of abscess, further interventions may be needed for other fistula-related symptoms such as discharge. Diseases such as tuberculosis, Crohn's disease, and malignancy can result in secondary anal fistulae.(10) Ano-rectal trauma or iatrogenic injuries during perineal operations can also cause an anal fistula.

Clinical presentation

Patients with an ano-rectal abscess may present with pain, swelling, and erythema over the abscess site. However, a deep-seated abscess may present with vague pain in the anal region and fever. The chronic stage or anal fistula usually presents with discharge from external or internal openings (through single or multiple external openings); discharge may consist of pus, fecal matter, and flatus. Sometimes there is no external opening, and the patient complains of discharge from the anus.

Differential diagnosis:

Anal fistula needs to be differentiated from:

- Furunculosis
- Hidradenitis suppurativa
- Pilonidal sinus
- Actinomycosis
- Lymphogranuloma venereum
- Granuloma inguinale

Types and classification

Anal fistulae have been classified in different ways by different authors, some of which are enlisted below. The Parks' classification is the most widely used because of its simplicity and ease of use. This classification is based on the relationship of the fistula tract to the anal sphincter muscles.

Parks Classification (11)

1. Intersphincteric fistula
2. Trans sphincteric fistula
3. Supra sphincteric fistula
4. Extra sphincteric fistula

There are multiple subtypes in each group. However, Park's classification is not applicable in many fistula cases, and up to 20% of the fistula patients cannot be classified by the Parks' classification.(12)

The American Society of Colon and Rectal Surgeons (ASCRS) Classification (13)

This classification is based on the complexity of the disease.

1. Simple Fistula: intersphincteric or low transsphincteric fistulas involving <30% of the external sphincter. In this type, fistulotomy can be performed without risk of incontinence.
2. Complex Fistula: fistulas with more muscle involvement, anterior fistulas in female patients, recurrent fistulas, and those associated with preexisting fecal incontinence, inflammatory bowel disease, or radiation.

Radiological classifications (St. James University Classification) (14)

This classification has been widely accepted by radiologists.

1. Simple linear intersphincteric fistula (Grade I)
2. Intersphincteric fistula with abscess or secondary tract (Grade II)
3. Simple trans-sphincteric fistula (Grade III)
4. Trans-sphincteric fistula with abscess or secondary tract within the ischiorectal fossa (Grade IV)
5. Supralevator and translevator disease (Grade V)

Assessment and investigations

Detailed history pertaining to anal fistula:

A patient's detailed history should include duration of symptoms, bowel habits, abdominal symptoms, details of all past surgeries (including obstetric), and history of any minor or major incontinence. Symptoms suggestive of other diseases related to fistulas like tuberculosis, Crohn's disease, malignancy, and presence of comorbid conditions such as diabetes, immunocompromised status should be determined before planning surgery.(13)

Anorectal examination

The perineum should be examined for the presence of any swelling, induration, tenderness, and external openings. An external opening may be single or multiple

and can extend to the scrotum, far laterally over the gluteal region, thighs, and rarely to the abdominal wall. If external openings are found, they should be traced towards the anal verge for the presence of subcutaneous cord-like induration. The intersphincteric groove should be palpated for any tenderness. A good digital rectal examination and anoscopy should follow to identify the internal opening. The internal opening can be felt as an area of induration or puckering, and sometimes pus can be seen exuding from it on anoscopy. It is not advisable to do probing of the external opening in the out-patient. The purpose of a thorough examination is to delineate the trajectory of the primary and possibly secondary fistula tracts and identify any evidence of ongoing sepsis (as evidenced by fluctuance, purulence, or skin changes).(13) It is of critical importance to describe the location of all perceived openings (anterior/posterior, right or left lateral), which helps for operative planning and positioning for definitive surgery. In some cases, a cord of the chronic fistula tract is palpable.(15) In such cases, the amount of muscle involved can be inferred with a digital examination.

Endoanal ultrasound or magnetic resonance imaging should be considered in patients with vague signs of anorectal abscess, multiple fistula tracts, and suspicion of inflammatory bowel disease or tuberculosis. Imaging is also useful to assess the integrity and function of the sphincter muscles in patients with previous failed operations. Furthermore, a CT scan is indicated when the pathology spreads to the abdominal wall or thigh. X-ray fistulography is not useful due to poor accuracy and provides no information about sphincters and their relation with the fistula tract.

Perineal and endoanal ultrasound is useful for delineating complex fistula tracts, and the correlation with intraoperative examination is 90% to 94%.(16) Injection of hydrogen peroxide through the external opening helps define the internal opening, secondary tracts, and abscess cavities. It is generally tolerated well though discomfort is commonly reported.(17, 18) The specificity decreases as the tract ascends high due to a greater interface between the tract and the rectal wall.

Pelvic magnetic resonance imaging (MRI) or MR Fistulogram is more useful for delineating complex, supra-sphincteric, and extra-sphincteric fistulae, as it is less operator-dependent than endoanal ultrasound. In up to 90% of cases, it corroborates correct anatomy and impacts the therapeutic decisions up to 75% of the time.(19, 20)

A meta-analysis comparing MRI with endoanal ultrasound for the assessment of cryptoglandular and Crohn's anal fistula found a similar sensitivity [0.87 (95 % confidence interval (CI) 0.63–0.96); 0.87 (95 % CI 0.70–0.95)] though higher specificity for MRI (0.69 vs 0.43).(21) Endoanal ultrasound showed better detection of the internal opening.(21) MRI is considered the gold standard and advocated to be performed preoperatively in all cases of complex fistulae.

Other investigations

Additional investigations may be required in some patients. If inflammatory bowel disease or malignancy is suspected, a colonoscopy should be undertaken. Patients should also be investigated for the presence of comorbidities like diabetes mellitus, tuberculosis, and other immunocompromising diseases.

ACRSI recommendations

- A detailed history and physical examination, including proctoscopy and digital examination, should be performed in all cases of anal fistulas. Symptoms, risk factors, location of internal and external openings, fistula tracts, and presence of infection should be assessed in detail. A note of sphincter integrity and continence should be made in all patients. (Strong recommendation based on very-low-quality evidence, 1C)
- Additional imaging techniques, preferably endoanal ultrasound or magnetic resonance imaging, should be considered in Complex fistula patients to guide management. (Strong recommendation based on very-low-quality evidence, 1C)

Anorectal abscess management

Most anorectal abscesses are cryptoglandular in origin caused by plugging of the anal glands.(22, 23) Skin furunculosis, hidradenitis, Crohn's disease, tuberculosis, STD, and postoperative complication of anal operations may be other causes.(24, 25) Depending upon the location of the pus, they are classified into submucosal abscess/intersphincteric abscess, perianal abscess, ischiorectal abscess, deep postanal abscess, and supralelevator abscess.(26)

An anorectal abscess is more commonly seen in males and during the third and fourth decades of life.(27, 28) The immunocompromised patients and individuals who engage in receptive anal sex are at higher risk of developing anorectal abscess.(27, 29, 30) The majority are due to crypto-glandular infection (90% to 95%) with bacteria of intestinal origin, whereas a small percentage could be due to perianal skin or subcutaneous infection with Staphylococcus or Streptococcus bacteria.(13, 31) There are other specific causes such as Crohn's Disease, IBD, tuberculosis, trauma, leukemia, lymphoma, STD, diverticulitis, infected anal fissure, etc. to account for another small percentage of these abscesses.(13, 15, 24, 32, 33)

All anorectal abscesses should be treated primarily with incision and drainage at the earliest. Delay can result in

the prolongation of infection, leading to more tissue destruction and subsequent sphincter dysfunction. The incision should be adequately sized to unroof the cavity and provide sufficient drainage close to the anal verge to minimize the length of a potential fistula. As in any other abscess, all loculi should be broken, cavity scooped of all sloughed tissue, cleaned, and packed for the purpose of hemostasis on the table. An attempt should be made to identify the internal opening to ensure if the same is due to fistulous etiology. This can be ascertained by looking for pus discharge from the site of internal opening or injecting diluted methylene blue in the decompressed abscess cavity prior to the incision. Documentation of the fistulous nature of the abscess should prompt an experienced hand to do a primary fistulotomy as a definitive surgery, lest the patient will report back with a fistula at a later date.(34-36)

Factors that influence this decision include the patient's general condition, type and size of the abscess, and the recurrent status. Pus may be sent for culture sensitivity as it may help in establishing the organism responsible. Postoperatively analgesic and laxatives are recommended. Antibiotics may be recommended if the patient is suffering from comorbid conditions like diabetes, immunocompromised status, prosthetic cardiac valve, or systemic sepsis.(32)

Dressings should include irrigation of the abscess cavity, especially after every act of defecation. The wound should not be packed but left to freely drain and collapse by just covering the mouth of the wound.(33)

The recurrence rate is high in abscesses, reaching up to 50% in horseshoe abscesses.(37) Factors associated with recurrence and the need for early repeat drainage are abscess location, incomplete initial drainage, failure to break up loculations within the abscess, missed abscess, and undiagnosed fistula.(37)

A meta-analysis of 6 trials involving 479 subjects, comparing incision and drainage of perianal abscess alone vs incision and drainage with fistula treatment, demonstrated a significant reduction in recurrence, persistent abscess/fistula, or repeat surgery with concomitant fistula surgery (pooled RR = 0.13, 95% CI = 0.07-0.24) and showed no significant difference in incontinence at one year (pooled RR 3.06, 95% CI = 0.7-13.45) though the studies were heterogeneous.(9)

A recent randomized trial among 200 consecutive patients demonstrated that drainage of perianal abscesses with concomitant fistula treatment vs without fistula treatment was effective and safe when performed by experienced surgeons, with a significantly lower recurrence rate (6% vs 44% at 12 months, $P < 0.001$; 10% vs 70% at a median follow-up of 31 months, $P < 0.001$) and showed no significant difference in incontinence compared with the abscess treatment without fistula drainage.(38)

ACRSI recommendations

- Patients with acute anorectal abscess should be treated with incision and drainage at the earliest. (Strong recommendation based on very-low-quality evidence, 1C)
- Simultaneous fistulotomy with incision and drainage of the abscess may be considered in selected patients. (Strong recommendation based on moderate-quality evidence, 1B)
- In the treatment of uncomplicated anorectal abscess, antibiotics have a limited role. (Strong recommendation based on moderate-quality evidence, 1B)
- Antibiotics should be considered in presence of acute anorectal sepsis, immunocompromised patients and in patients with prosthetic heart valves. (Weak recommendation based on low-quality evidence, 2C)

Anal fistula management

A permanent cure of anal fistula is possible only with surgical treatment. The aim of the surgery is to drain the septic focus, completely obliterate the fistula with minimal injury to the sphincter complex, and attain healing with satisfactory functional outcomes. A suitable surgical option should be chosen based on the etiology, location, symptoms, comorbidities, resources, and the experience of the surgeon. Daycare treatment is usually sufficient for most fistulas.

Management of simple fistulas

Simple or low fistulas where the sphincter involvement is less than 1/3 or the fistula is below the dentate line are best treated by a fistulotomy. Fistulotomy includes completely laying open the fistula with the division of all anal sphincters involved. Also, secondary tracks, if any, are identified and are adequately drained. The average healing rate is 93.7%, while any postoperative continence impairment reported is 12.7%.(39) Visscher et al. reported that 3% of patients had incontinence for solid, 3% for liquid stools, 24% for gas, and 4% of patients needed sanitary pads for patients with simple fistulas.(40) Koperen et al. reported soiling reported in 41% of patients who had undergone fistulotomy.(41)

Postoperative incontinence rates vary across studies, probably due to differences in the definition of incontinence (ranging from occasional stains on underwear to frank incontinence of stools) and follow-up.(13) Also, postoperative incontinence may be associated with factors such as preoperative incontinence, recurrent disease, female sex, complex fistulas, and prior fistula surgery. As a part of decision making, the risk of incontinence vs recurrence should be taken into consideration and explained in detail to the

patient. The incontinence is mainly soiling and flatus incontinence.(42, 43)

Marsupialization of fistulotomy wounds for simple fistula-in-ano is associated with a significantly shorter healing time but similar recurrence, pain scores at 24 h, and incontinence rates compared with omitting marsupialization.(44) In a prospective randomized controlled trial comparing fistulectomy versus fistulotomy with marsupialization in low fistulas, it was found that there was no statistically significant difference in the mean operating time, mean operation wound size, mean postoperative pain score, rate of surgical site infection, recurrence rate, incontinence, and postoperative hospital stay between the two groups. Thus the authors concluded that in comparison to a fistulectomy, a fistulotomy with marsupialization results in faster wound healing and a shorter duration of wound discharge and is recommended for simple low fistulas.(45) In another randomized controlled trial, the authors similarly concluded that in comparison to a fistulectomy, a fistulotomy with marsupialization results in faster healing and a shorter duration of wound discharge without increasing the operating time.(46) Although, a recent meta-analysis concluded that there is no conclusive evidence if fistulectomy or fistulotomy procedure is better in treating low anal fistula.(47) There are many other procedures for simple low fistulas, but the simplicity and success rate of fistulotomy scores higher.

Management of complex fistulas

The management of complex anal fistulas is more difficult as they likely have higher failure rates and functional disability.(15) Surgical treatment of complex fistula may be undertaken using: setons (draining or cutting setons), fistulotomy or fistulectomy (primary or staged, with or without sphincteroplasty), endorectal advancement flap, anal fistula plug, fibrin glue, laser (fistula laser closure [FiLaC]), ligation of intersphincteric fistula tract (LIFT), video-assisted anal fistula treatment (VAAFT), stem cell therapy, etc.

Draining seton

A draining seton (e.g., Silastic vessel loop) is placed through a fistula, usually at the first assessment, and is tied loosely upon itself with a silk suture.(48) The purpose of keeping a loose draining seton through a complex fistula is to prevent the recurrence of perianal sepsis and maintain the fistula tract open prior to a definitive procedure.(49, 50) It prevents closure of the fistula tract and the external opening. It may also decrease the size of the wound and fistula tract over time, specifically if the external opening is located some distance away from the anal verge.(48) Draining seton is a stepping stone to a definitive surgery and does not cure the fistula. It is particularly useful in Crohn's fistula, where it is kept in place till the time biologics (anti- TNF) start acting.(51)

Cutting Seton

In this procedure, the seton is passed during the surgery and is left in place and tightened at regular intervals to allow gradual division of the sphincter. Cutting seton helps heal the anal fistula with the development of a fibrotic tract. The longer healing times and higher risk of incontinence, especially in complex fistula, may limit its use in this scenario. Even though individual studies suggest that a cutting seton is effective (52) and safe for the treatment of complex cryptoglandular anal fistulas, this can result in anal sphincter functional impairment, and, therefore, the surgeon should use his judgment and experience to perform this procedure with caution.

Fistulotomy / Fistulectomy with sphincter repair

This procedure involves either excising the entire fistula tract along with its branches or laying open the tract after dividing the sphincter (division should be limited below the puborectalis sling). The sphincter muscles are primarily reconstructed immediately. It combines the success rate of fistulotomy/ fistulectomy at the same time overcomes associated incontinence by primary repair of the sphincter. A recent systematic review concluded that fistulectomy and primary sphincteroplasty could be a therapeutic option for complex fistula given the high success rates and low risk of postoperative fecal incontinence vs simple fistulotomy.(53) The overall success rate was 93.2%, while the postoperative worsening continence rate (mainly post-defecation soiling) was 12.4%. In almost all cases, the anorectal manometry parameters remained unchanged. The quality of life, when evaluated, improved significantly. Another advantage of this procedure is that the continence can also be improved in those cases where the sphincter has been divided in a previous surgery and repaired in the present surgery.(54) This procedure can be performed in most complex fistulas and can work as a definitive surgery after a failed conservative procedure. It remains the procedure of choice in recurrent fistulas, especially those with preoperative compromised incontinence.

Endorectal Advancement Flap

An endorectal advancement flap consists of curetting or coring out the fistula tract, excising the internal opening, and mobilizing (with intact blood supply) a partial-thickness flap with anorectal mucosa, submucosa, and part of muscles to cover the underline excised internal opening. Primary healing rates of >65% are reported with this surgery.(55-58) For those with recurrence, it is reasonable to repeat the procedure as it often results in good healing.(55, 58) Factors associated with failure of this technique may include functional impairment of the anal sphincter, endoscopic defects or manometric defects in the anal sphincter, Crohn's disease, complex fistula, and recurrent fistula.(59, 60) The reported rate of incontinence ranged from 7.8% to 13.3%.

A Cochrane systematic review demonstrated significantly higher recurrence rates in the glue plus flap group vs the flap only technique(24), suggesting that the hybrid technique should not be used. This could possibly result from the prevention of adequate drainage of the fistula tract during healing when the glue was used concomitantly.(48)

Fibrin Glue

Fibrin glue or sealant is a tissue adhesive that stimulates a fibrotic reaction in the fistula tract and is ultimately replaced by the natural tissue closing the tract.(61) It is a relatively safe and conservative procedure, but with variable results. In a randomized control trial with a 1-year follow-up period, only 15 out of 38 patients healed – a success rate of less than 50%. The only advantage was less postoperative pain and a short hospital stay.(62) A systematic review suggested that fibrin glue may not be efficacious because it either falls out after clotting or is probably the wrong biomaterial. The review demonstrated that the success rates deteriorated with time across geographies.(63). In another systematic review, the authors concluded that the limited collected data do not support the use of fibrin glue.(64) Thus, fibrin glue as a standalone procedure for complex fistula is not very effective. It is contraindicated in the presence of sepsis or straight short tract.

Anal Fistula Plug

The bioprosthetic anal fistula plug is an acellular collagen matrix derived from the submucosa of the porcine small intestine (Biodesign®). It is used to close the primary internal anal opening and it provides a scaffold for native tissue in-growth that obliterates the fistula tract. Initial studies showed a high success rate.(65) However, a systematic review concludes that fistula plug has a moderate success rate of 35% to 87%.(66) Another review shows that healing rates of 50% to 60% can be expected on treating complex anal fistula with a fistula plug, and with a plug-extrusion rate healing of 10% to 20% with a low complication rate.(67) The Gore Bio-A® Fistula Plug is a delayed absorbable synthetic plug with a function similar to the collagen plug. A systematic review of this plug reported healing rates to be between 15.8% and 72.7% at a follow-up ranging between 2 and 19 months.(68) In a comparative study comparing the Cook Biodesign® plug with the Gore Bio-A® plug, the overall procedural success rate in the Gore group was 54.5 percent (6 of 11) versus 12.5 percent (2 of 16) in the Cook group. The numbers were very small, though to give a significant opinion.(69) Overall, many studies demonstrate that <50% healing in patients with complex fistula.(70-72)

LIFT

In this technique, the intersphincteric plane is dissected, and the transsphincteric fistula tract is identified and encircled. The tract is then ligated and divided, and the distal tract is curetted through the external opening. The intersphincteric wound is closed loosely. This technique has recently gained popularity for treating both simple and complex fistulas.(15) Three systematic review articles suggested that healing rates for LIFT procedure vary between 70.6% and 76.4%, a healing time of 4 to 8 weeks, with limited morbidity and rare alterations in fecal continence.(73-75) Some modified techniques are sometimes practiced, such as using seton prior to LIFT, suturing within the anal canal to close the internal opening, using a biological mesh or graft for occluding the intersphincteric space (BioLIFT), performing simultaneous LIFT and endorectal advancement flap, using a fistula plug for closing the external opening.(76-81) Though the data are limited, the healing and functional outcomes are comparable with the classic LIFT. Recurrences are reported after 2-8 months. A repeat LIFT procedure may be performed in case of failures and has a good (>50%) healing rate.(78)

FiLaC

Fistula laser closure (FiLaC) is a new technology that uses a radial emitting laser probe to erode or seal the complex fistula tract. It seems to be a simple, safe, effective, minimally invasive, sphincter-saving technique. Few case series (11-117 patients) have been published, showing 33% to 82% healing over a median follow-up of 6 to 30 months.(82) Overall, patients did not report major worsening of continence postoperatively.(82-84)

Video-assisted anal fistula treatment (VAAFT)

Another relatively novel technology that has become popular is video-assisted anal fistula treatment (VAAFT). It ablates the fistula tract under direct visualization allowing closure of the internal opening as well as the tract. As the fistula tract can be navigated under direct visualization without cutting tissue, this sphincter-saving technique is useful in complex fistulas.(48) The outcomes using this technique have been synthesized in two recent systematic reviews.(85, 86) The success rates were 76% and 85%, although it is not very clear what percentage of cases were high and complex. The respective authors concluded that VAAFT might be considered an effective diagnostic tool and a safe method (85), for the treatment of anal fistula with minimal incontinence risk, minimal hospital stay, and early return to work.(86)

Stem cell

In this procedure, adipose tissue-derived stem cells are used to close the fistula tracts. In a small series prospective controlled study, the success rate was around 54%.⁽⁸⁷⁾ In a recent randomized controlled trial, the healing rate was 63.8%, and the authors concluded that this procedure might represent a safe, effective, and inexpensive option for the treatment of complex fistula-in-ano.⁽⁸⁸⁾ In another meta-analysis and systematic review of the use of stem cells to treat Crohn's fistula, the healing rates vary from 61.7% to 77.95%.⁽⁸⁹⁾ The authors concluded that stem cell was a promising method in the treatment of Crohn's fistula based on its higher efficacy and lower incidence of adverse events. Treatment by stem cells is a very new procedure and needs more validation before it can be accepted as a standard procedure for anal fistula treatment.

Recurrent anal fistula

Recurrence after abscess/fistula surgery is a worrying complication for most surgeons; increasingly worrisome if the recurrence is multiple. High-quality evidence showed that recurrence was associated with high trans-sphincteric fistula, failure to identify the internal opening, and horseshoe extensions. Moderate-quality evidence suggested an association with prior anal surgery, seton placement surgery, and multiple fistula tracts.⁽⁹⁰⁾ High inter-sphincteric extensions can often be missed or left out during surgery and can also contribute to the recurrence.

A recurrent fistula should be assessed more thoroughly pre-operatively. A detailed history eliciting the time of recurrence, incontinence issues, nature of the previous surgery, and any other associated medical illness should be obtained. It is advisable to get the MRI done in recurrent fistula to know the cause of recurrence and plan out the forthcoming surgery. Colonoscopy may be needed to rule out suspected colonic pathology like IBD. A biopsy may be done if one suspects malignancy or tuberculosis.

The surgeon should be clear in their mind about the cause of the previous recurrence and the extent of the disease while planning the subsequent surgery. If the previous surgery is sphincter-saving, the same can be repeated, or a sphincter cutting procedure can be done, which has a lower recurrence rate. It is important to remember that dividing the sphincter multiple times can

increase the risk of incontinence. Post-operative management is equally important to prevent another recurrence. The wound should be periodically assessed to make sure that the deeper parts of the wound heal first.

ACRSI recommendations

- Simple anal fistulas may be treated by fistulotomy. It results in a reliable cure with good patient satisfaction. (Strong recommendation based on moderate-quality evidence, 1B)
- Fibrin glue has limited use for treating simple and complex anal fistulas. (Weak recommendation based on moderate-quality evidence, 2B)
- Cutting seton has a limited role in treatment of simple and complex anal fistula. (Weak recommendations based on moderate-quality evidence, 2B).
- Draining seton may be used for the control of anorectal sepsis and in patients with secondary anal fistula (Crohn's, tuberculosis).
- Endorectal advancement flaps may be used in the treatment of complex fistula. (Strong recommendation based on low-quality evidence, 1C)
- The anal fistula plug and glue have limited role in treating anal fistulas. (Weak recommendation based on moderate-quality evidence, 2B)
- Ligation of the intersphincteric fistula tract (LIFT) procedure may be used to treat simple and complex anal fistulas. (Strong recommendation based on moderate-quality evidence, 1B)
- Newer technologies such as video-assisted anal fistula treatment (VAAFT) and application of diode laser may be used for treating complex fistulas by surgeons trained and experienced in using these techniques (Strong recommendation based on very low-quality evidence, 1C)
- Fistulectomy with primary sphincter repair is an effective treatment option for complex fistula or in cases of recurrent fistulas, or in patients with preoperative compromised incontinence (Strong recommendation based on low-quality evidence, 1C)

Fistula in special circumstances

Anal Fistula not arising due to cryptoglandular infection can arise due to secondary causes such as Crohn's, trauma, radiation, cancers, HIV, tuberculosis, or infected fissure in ano. These are termed secondary fistulas and have unusual appearances or locations.(13)

When these are suspected, thorough investigations should be conducted to evaluate the cause of fistula and treat accordingly. Anterior fistulas in women are also considered complex fistulas and need special consideration.(13)

Apart from the local signs and symptoms of anal fistulas, most of these patients would present with other constitutional or systemic signs and symptoms related to their specific etiologies. Thorough clinical evaluation and suspecting a secondary etiology helps the clinicians to investigate these cases with an additional test to confirm or refute a particular diagnosis.

Tuberculosis should be considered a cause whenever the fistulas are recurrent with multiple openings, especially in an endemic area. Evening rise of temperature with anorexia weight loss could be associated symptoms. One may notice the presence of inguinal nodes in these patients. Colonoscopy, X-ray Chest, TB PCR, and TB culture should be carried out as per need. Postoperative histological evaluation of the specimen is a must and should be carried out on all fistula specimens. Although in certain cases, the fistula may heal after antituberculosis treatment, surgical removal of tuberculous fistulas is necessarily recommended as standard procedure.(91, 92)

Mucinous adenocarcinoma associated with perianal fistula is a rare malignancy that accounts for 3% to 11% of total anal cancers.(93) The etiology remain elusive with the malignant tumor arising de novo, which could manifest as fistula, or it may originate from a chronic perianal fistula or an abscess cavity. Early diagnosis may be challenging in carcinoma associated with anal

fistula because of the insidious nature of the disease together with masking of symptoms. Malignancy should be suspected when a chronic perianal fistula is persisting with continued mucinous discharge even after the surgery. Multiple biopsies from suspected lesions should be taken, given that there may be isolated areas of malignant transformation separated by inflammatory zone. Radical cure with abdominoperineal resection with a permanent stoma is the recommended treatment option.(94-97)

Myocutaneous flaps are sometimes required to reconstruct the large defects created by wide excision.

Crohn's

Perianal fistula is a common manifestation of Crohn's disease, accounting for 17% to 43% of the patients with Crohn's disease.(98, 99) These patients present with more systemic symptoms associated with the disease and more common with colonic involvement.(98, 99) Deep ulcerations and high tracts should raise suspicion in these patients. Rectovaginal involvement in female patients is also more attributable to Crohn's.(98, 100) After confirmation of the diagnosis, active Crohn's disease should be treated systemically first. In the presence of active sepsis, which may require drainage, a draining seton may be inserted to allow the sepsis to settle.(101) This should be followed with definitive treatment for Crohn's disease, including anti-TNF drugs.(102) In cases where the disease is quiescent and under control, one may offer anorectal flap fibrin glue or a fistula plug to these patients. Whichever procedure is used, a higher recurrence rate is a norm in these patients.(31)

HIV

Immunodeficient otherwise healthy patients with normal CD4 and CD8 counts can be treated like any other fistula, whereas those with low counts should be offered draining setons under antibiotic cover. large wounds should be avoided as healing is poor.(103)

References

- Forootan M, Bagheri N, Darvishi M. Chronic constipation: A review of literature. *Medicine (Baltimore)*. 2018;97(20):e10631.
- Hokkanen SR, Boxall N, Khalid JM, Bennett D, Patel H. Prevalence of anal fistula in the United Kingdom. *World J Clin Cases*. 2019;7(14):1795.
- Zanotti C, Martinez-Puente C, Pascual I, Pascual M, Herreros D, García-Olmo D. An assessment of the incidence of fistula-in-ano in four countries of the European Union. *Int J Colorectal Dis*. 2007;22(12):1459-1462.
- Yamana T. Japanese practice guidelines for anal disorders II. Anal fistula. *JARC*. 2018;2(3):103-109.
- Vyas AK, Katlana A, Singh A, Thakur S, Yadav A. Incidence of low fistula in ano and results of fistulotomy in rural tertiary centre. *Ann Int Med Den Res*. 2017;3(3).
- Guyatt G, Gutterman D, Baumann MH, et al. Grading strength of recommendations and quality of evidence in clinical guidelines: report from an American College of Chest Physicians task force. *Chest*. 2006;129(1):174-181.
- H C. Ueber die analen Divertikel der Rectumsschleimhaut und ihre Beziehung zu den Analfisteln. *Med Jahr*. 1878;(8):419-427.
- Herrmann G, Desfosses L. Sur la muqueuse de la région cloacale du rectum. *Compt rend Acad d sc*. 1880;90:1301-1302.
- He Z, Du J, Wu K, et al. Formation rate of secondary anal fistula after incision and drainage of perianal Sepsis and analysis of risk factors. *BMC surgery*. 2020;20(1):1-7.
- Oliver I, Lacueva FJ, Pérez Vicente F, Arroyo A, Ferrer R, Cansado P, et al. Randomized clinical trial comparing simple drainage of anorectal abscess with and without fistula track treatment. *Int J Colorectal Dis*. 2003;18:107-110.
- Akcapulu N, Dere Ö, Zaim G, Soy HEA, Özmen T, Doğrul AB. A retrospective analysis of 93 cases with anorectal abscess in a rural state hospital. *Türk J Surg/ Ulus Cerrahi Derg*. 2015;31(1):5.
- Parks A. Pathogenesis and treatment of fistula-in-ano. *BMJ*. 1961;1(5224):463.
- Tozer P, Sala S, Cianci V, et al. Fistulotomy in the tertiary setting can achieve high rates of fistula cure with an acceptable risk of deterioration in continence. *J Gastrointest Surg*. 2013;17(11):1960-1965.
- Steele SR, Kumar R, Feingold DL, Rafferty JL, Buie WD; Standards Practice Task Force of the American Society of Colon and Rectal Surgeons. Practice parameters for the management of perianal abscess and fistula-in-ano. *Dis Colon Rectum*. 2011;54(12):1465-1474.
- Morris J, Spencer JA, Ambrose NS. MR imaging classification of perianal fistulas and its implications for patient management. *Radiographics*. 2000;20(3):623-635.
- Bubbers EJ, Cologne KG. Management of complex anal fistulas. *Clin Colon Rectal Surg*. 2016;29(01):043-049.
- Ratto C, Grillo E, Parello A, Costamagna G, Doglietto G. Endoanal ultrasound-guided surgery for anal fistula. *Endoscopy*. 2005;37(08):722-728.
- Kim Y, Park YJ. Three-dimensional endoanal ultrasonographic assessment of an anal fistula with and without H2O2 enhancement. *World J Gastroenterol*. 2009;15(38):4810.
- Nagendranath C, Saravanan M, Sridhar C, Varughese M. Peroxide-enhanced endoanal ultrasound in preoperative assessment of complex fistula-in-ano. *Tech Coloproctol*. 2014;18(5):433-438.
- Buchanan G, Halligan S, Williams A, et al. Effect of MRI on clinical outcome of recurrent fistula-in-ano. *Lancet*. 2002;360(9346):1661-1662.
- Buchanan GN, Halligan S, Bartram CI, Williams AB, Tarroni D, Cohen CRG. Clinical examination, endosonography, and MR imaging in preoperative assessment of fistula in ano: comparison with outcome-based reference standard. *Radiology*. 2004;233(3):674-681.
- Siddiqui MR, Ashrafian H, Tozer P, et al. A diagnostic accuracy meta-analysis of endoanal ultrasound and MRI for perianal fistula assessment. *Dis Colon Rectum*. 2012;55(5):576-585.
- Schwandner O. Qualitätsindikatoren bei der Therapie der Analfisteln [Quality indicators in the treatment of anal fistulas]. *Chirurg*. 2019;90(4):270-278.
- Hadzhiev BD, Murdjeva MA. Immunopathological characteristics of cryptoglandular and Crohn's anorectal fistulas. *Folia Med (Plovdiv)*. 2010;52(4):5-12.
- Jacob TJ, Perakath B, Keighley MR. Surgical intervention for anorectal fistula. *Cochrane Database Syst Rev*. 2010;(5):CD006319. Published 2010 May 12.
- Ommer A, Herold A, Berg E, et al. Cryptoglandular anal fistulas. *Dtsch Arztebl Int*. 2011;108(42):707-713.
- Abcarian H. Anorectal infection: abscess-fistula. *Clin Colon Rectal Surg*. 2011;24(1):14-21.
- Turner SV, Singh J. Perirectal abscess. 2018.
- Hyman N. Anorectal abscess and fistula. *Prim Care*. 1999;26(1):69-80.
- Neto IJ, Wercka J, Cecchini AR, et al. Perianal abscess: a descriptive analysis of cases treated at the Hospital Santa Marcelina, São Paulo. *J. Coloproctol. (Rio J.)*. 2016 Jul;36:149-52.
- Kanstrup C, Perregaard H, Bertelsen CA. *Ugeskr Laeger*. 2019;181(9):V10180736.
- Marzo M, Felice C, Pugliese D, et al. Management of perianal fistulas in Crohn's disease: an up-to-date review. *World J Gastroenterol*. 2015;21(5):1394-1403.
- North JH Jr, Weber TK, Rodriguez-Bigas MA, Meropol NJ, Petrelli NJ. The management of infectious and noninfectious anorectal complications in patients with leukemia. *J Am Coll Surg*. 1996;183(4):322-328.
- Sigmon DF, Emmanuel B, Tuma F. Perianal Abscess. 2017.
- Tang CL, Chew SP, Seow-Choen F. Prospective randomized trial of drainage alone vs. drainage and fistulotomy for acute perianal abscesses with proven internal opening. *Dis Colon Rectum*. 1996;39(12):1415-1417.
- Vasilevsky CA, Gordon PH. The incidence of recurrent abscesses or fistula-in-ano following anorectal suppuration. *Dis Colon Rectum*. 1984;27(2):126-130.
- Schouten WR, van Vroonhoven TJ. Treatment of anorectal abscess with or without primary fistulectomy. Results of a prospective randomized trial. *Dis Colon Rectum*. 1991;34(1):60-63.
- Onaca N, Hirshberg A, Adar R. Early reoperation for perirectal abscess: a preventable complication. *Dis Colon Rectum*. 2001;44(10):1469-1473.
- Galanis I, Chatzimavroudis G, Christopoulos P, Makris J. Prospective randomized trial of simple drainage vs. drainage and initial fistula management for perianal abscess. *J Gastrointest & Dig System*. 2016;6(1).
- Litta F, Parello A, Ferri L, et al. Simple fistula-in-ano: is it all simple? A systematic review. *Tech Coloproctol*. 2021;25(4):385-399.
- Visscher AP, Schuur D, Roos R, Van der Mijnsbrugge GJ, Meijerink WJ, Felt-Bersma RJ. Long-term follow-up after surgery for simple and complex cryptoglandular fistulas: fecal incontinence and impact on quality of life. *Dis Colon Rectum*. 2015;58(5):533-539.
- van Koperen PJ, Wind J, Bemelman WA, Bakx R, Reitsma JB, Slors JF. Long-term functional outcome and risk factors for recurrence after surgical treatment for low and high perianal fistulas of cryptoglandular origin. *Dis Colon Rectum*. 2008;51(10):1475-1481.
- Bokhari S, Lindsey I. Incontinence following sphincter division for treatment of anal fistula. *Colorectal Dis*. 2010;12(7 Online):e135-e139.
- van Tets WF, Kuijpers HC. Continence disorders after anal fistulotomy. *Dis Colon Rectum*. 1994;37(12):1194-1197.
- Sahebally SM, O'Byrne L, Troy A, Byrnes KG, Burke J, McNamara D. A meta-analysis of marsupialisation versus none in the treatment of simple fistula-in-ano. *Int J Colorectal Dis*. 2021;36(3):429-436.

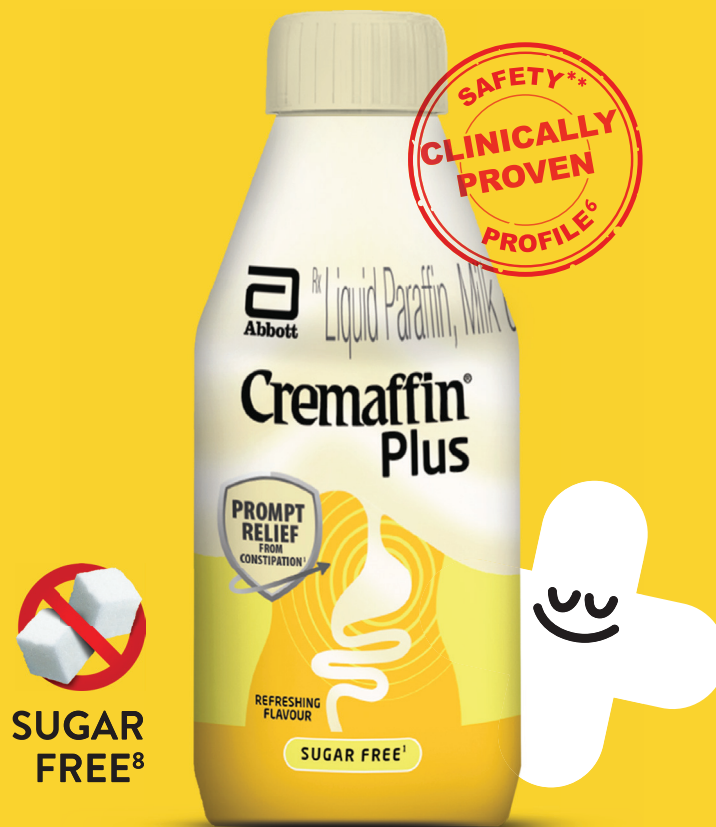45. Chalya PL, Mabula JB. Fistulectomy versus fistulotomy with marsupialisation in the treatment of low fistula-in- ano: a prospective randomized controlled trial. *Tanzan J Health Res.* 2013;15(3):193-198.
46. Jain BK, Vaibhaw K, Garg PK, Gupta S, Mohanty D. Comparison of a fistulectomy and a fistulotomy with marsupialization in the management of a simple anal fistula: a randomized, controlled pilot trial. *J Korean Soc Coloproctol.* 2012;28(2):78-82.
47. Xu Y, Liang S, Tang W. Meta-analysis of randomized clinical trials comparing fistulectomy versus fistulotomy for low anal fistula. *Springerplus.* 2016;5(1):1722. Published 2016 Oct 6.
48. Bubbers EJ, Cologne KG. Management of Complex Anal Fistulas. *Clin Colon Rectal Surg.* 2016;29(1):43-49.
49. Mushaya C, Bartlett L, Schulze B, Ho YH. Ligation of intersphincteric fistula tract compared with advancement flap for complex anorectal fistulas requiring initial seton drainage. *Am J Surg.* 2012;204(3):283-289.
50. Aboulain A, Kaji AH, Kumar RR. Early result of ligation of the intersphincteric fistula tract for fistula-in-ano. *Dis Colon Rectum.* 2011;54(3):289-292.
51. de Groof EJ, Sahami S, Lucas C, Ponsioen CY, Bemelman WA, Buskens CJ. Treatment of perianal fistula in Crohn's disease: a systematic review and meta-analysis comparing seton drainage and anti-tumour necrosis factor treatment. *Colorectal Dis.* 2016;18(7):667-675.
52. Andreou C, Zeindler J, Oertli D, Misteli H. Longterm outcome of anal fistula—A retrospective study. *Scientific reports.* 2020 Apr 16;10(1):1-7.
53. Ratto C, Litta F, Donisi L, Parello A. Fistulotomy or fistulectomy and primary sphincteroplasty for anal fistula (FIPS): a systematic review. *Tech Coloproctol.* 2015;19(7):391-400.
54. Arroyo A, Pérez-Legaz J, Moya P, et al. Fistulotomy and sphincter reconstruction in the treatment of complex fistula-in-ano: long-term clinical and manometric results. *Ann Surg.* 2012;255(5):935-939.
55. Jarrar A, Church J. Advancement flap repair: a good option for complex anorectal fistulas. *Dis Colon Rectum.* 2011;54(12):1537-1541.
56. Madbouly KM, El Shazly W, Abbas KS, Hussein AM. Ligation of intersphincteric fistula tract versus mucosal advancement flap in patients with high transsphincteric fistula-in-ano: a prospective randomized trial. *Dis Colon Rectum.* 2014;57(10):1202-1208.
57. Soltani A, Kaiser AM. Endorectal advancement flap for cryptoglandular or Crohn's fistula-in-ano. *Dis Colon Rectum.* 2010;53(4):486-495.
58. Mitalas LE, Gosselink MP, Zimmerman DD, Schouten WR. Repeat transanal advancement flap repair: impact on the overall healing rate of high transsphincteric fistulas and on fecal continence. *Dis Colon Rectum.* 2007;50(10):1508-1511.
59. Balciscueta Z, Uribe N, Balciscueta I, Andreu-Ballester JC, García-Granero E. Rectal advancement flap for the treatment of complex cryptoglandular anal fistulas: a systematic review and meta-analysis. *Int J Colorectal Dis.* 2017;32(5):599-609.
60. Stellingwerf ME, van Praag EM, Tozer PJ, Bemelman WA, Buskens CJ. Systematic review and meta-analysis of endorectal advancement flap and ligation of the intersphincteric fistula tract for cryptoglandular and Crohn's high perianal fistulas [published correction appears in *BJS Open.* 2020 Feb;4(1):166-167]. *BJS Open.* 2019;3(3):231-241. Published 2019 Jan 21.
61. Azizi R, Mohammadipour S. New techniques in anal fistula management. *Ann Colorectal Res.* 2014 Mar 1;2(1):1-7.
62. Altomare DF, Greco VJ, Tricomi N, et al. Seton or glue for trans-sphincteric anal fistulae: a prospective randomized crossover clinical trial. *Colorectal Dis.* 2011;13(1):82-86.
63. Kontovounisios C, Tekkis P, Tan E, Rasheed S, Darzi A, Wexner SD. Adoption and success rates of perineal procedures for fistula-in-ano: a systematic review. *Colorectal Dis.* 2016;18(5):441-458.
64. Cirocchi R, Farinella E, La Mura F, et al. Fibrin glue in the treatment of anal fistula: a systematic review. *Ann Surg Innov Res.* 2009;3:12. Published 2009 Nov 14.
65. Champagne BJ, O'Connor LM, Ferguson M, Orangio GR, Schertzer ME, Armstrong DN. Efficacy of anal fistula plug in closure of cryptoglandular fistulas: long-term follow-up. *Dis Colon Rectum.* 2006;49(12):1817-1821.
66. Garg P, Song J, Bhatia A, Kalia H, Menon GR. The efficacy of anal fistula plug in fistula-in-ano: a systematic review. *Colorectal Dis.* 2010;12(10):965-970.
67. Köckerling F, Alam NN, Narang SK, Daniels IR, Smart NJ. Treatment of Fistula-In-Ano with Fistula Plug - a Review Under Special Consideration of the Technique. *Front Surg.* 2015;2:55. Published 2015 Oct 16.
68. Narang SK, Jones C, Alam NN, Daniels IR, Smart NJ. Delayed absorbable synthetic plug (GORE® BIO-A®) for the treatment of fistula-in-ano: a systematic review. *Colorectal Dis.* 2016;18(1):37-44.
69. Buchberg B, Masoomi H, Choi J, Bergman H, Mills S, Stamos MJ. A tale of two (anal fistula) plugs: is there a difference in short-term outcomes?. *Am Surg.* 2010;76(10):1150-1153.
70. El-Gazzaz G, Zutshi M, Hull T. A retrospective review of chronic anal fistulae treated by anal fistulae plug. *Colorectal Dis.* 2010;12(5):442-447.
71. Kleif J, Hagen K, Wille-Jørgensen P. Acceptable results using plug for the treatment of complex anal fistulas. *Dan Med Bull.* 2011;58(3):A4254.
72. Stamos MJ, Snyder M, Robb BW, et al. Prospective multicenter study of a synthetic bioabsorbable anal fistula plug to treat cryptoglandular transsphincteric anal fistulas. *Dis Colon Rectum.* 2015;58(3):344-351.
73. Hong KD, Kang S, Kalaskar S, Wexner SD. Ligation of intersphincteric fistula tract (LIFT) to treat anal fistula: systematic review and meta-analysis. *Tech Coloproctol.* 2014;18(8):685-691.
74. Vergara-Fernandez O, Espino-Urbina LA. Ligation of intersphincteric fistula tract: what is the evidence in a review?. *World J Gastroenterol.* 2013;19(40):6805-6813.
75. Zarak-Schmidt S, Perdawood SK. Management of anal fistula by ligation of the intersphincteric fistula tract - a systematic review. *Dan Med J.* 2014;61(12):A4977.
76. Sirany AM, Nygaard RM, Morken JJ. The ligation of the intersphincteric fistula tract procedure for anal fistula: a mixed bag of results. *Dis Colon Rectum.* 2015;58(6):604-612.
77. Han JG, Yi BQ, Wang ZJ, et al. Ligation of the intersphincteric fistula tract plus a bioprosthetic anal fistula plug (LIFT-Plug): a new technique for fistula-in-ano. *Colorectal Dis.* 2013;15(5):582-586.
78. Wallin UG, Mellgren AF, Madoff RD, Goldberg SM. Does ligation of the intersphincteric fistula tract raise the bar in fistula surgery?. *Dis Colon Rectum.* 2012;55(11):1173-1178.
79. Ellis CN. Outcomes with the use of bioprosthetic grafts to reinforce the ligation of the intersphincteric fistula tract (BioLIFT procedure) for the management of complex anal fistulas. *Dis Colon Rectum.* 2010;53(10):1361-1364.
80. van Onkelen RS, Gosselink MP, Schouten WR. Is it possible to improve the outcome of transanal advancement flap repair for high transsphincteric fistulas by additional ligation of the intersphincteric fistula tract?. *Dis Colon Rectum.* 2012;55(2):163-166.
81. Han JG, Wang ZJ, Zheng Y, et al. Ligation of Intersphincteric Fistula Tract vs Ligation of the Intersphincteric Fistula Tract Plus a Bioprosthetic Anal Fistula Plug Procedure in Patients With Transsphincteric Anal Fistula: Early Results of a Multicenter Prospective Randomized Trial. *Ann Surg.* 2016;264(6):917-922.
82. Marref I, Spindler L, Aubert M, et al. The optimal indication for FiLaC® is high trans-sphincteric fistula-in-ano: a prospective cohort of 69 consecutive patients. *Tech Coloproctol.* 2019;23(9):893-897.
83. Giamundo P, Geraci M, Tibaldi L, Valente M. Closure of fistula-in-ano with laser--FiLaC™: an effective novel sphincter-saving procedure for complex disease. *Colorectal Dis.* 2014;16(2):110-115.
84. Wilhelm A, Fiebig A, Krawczak M. Five years of experience with the FiLaC™ laser for fistula-in-ano management: long-term follow-up from a single institution. *Tech Coloproctol.* 2017;21(4):269-276.

85. Emile SH, Elfeki H, Shalaby M, Sakr A. A Systematic review and meta-analysis of the efficacy and safety of video-assisted anal fistula treatment (VAAFT). *Surg Endosc.* 2018;32(4):2084-2093.
86. Garg P, Singh P. Video-Assisted Anal Fistula Treatment (VAAFT) in Cryptoglandular fistula-in-ano: A systematic review and proportional meta-analysis. *Int J Surg.* 2017;46:85-91.
87. Zhang Y, Ni M, Zhou C, et al. Autologous adipose-derived stem cells for the treatment of complex cryptoglandular perianal fistula: a prospective case-control study. *Stem Cell Res Ther.* 2020;11(1):475. Published 2020 Nov 10.
88. Ascanelli S, Zamboni P, Campioni D, et al. Efficacy and Safety of Treatment of Complex Idiopathic Fistula-in-Ano Using Autologous Centrifuged Adipose Tissue Containing Progenitor Cells: A Randomized Controlled Trial. *Dis Colon Rectum.* 2021;64(10):1276-1285.
89. Cao Y, Su Q, Zhang B, Shen F, Li S. Efficacy of stem cells therapy for Crohn's fistula: a meta-analysis and systematic review. *Stem Cell Res Ther.* 2021;12(1):32. Published 2021 Jan 7.
90. Mei Z, Wang Q, Zhang Y, et al. Risk Factors for Recurrence after anal fistula surgery: A meta-analysis. *Int J Surg.* 2019;69:153-164.
91. Gupta PJ. Ano-perianal tuberculosis--solving a clinical dilemma. *Afr Health Sci.* 2005;5(4):345-347.
92. Bambrule P, Sheikh MTM, Mittal T, et al. Tuberculous fistula-in-ano. *Indian J Colo-Rectal Surg.* 2019;2(3):97.
93. Schaffzin DM, Stahl TJ, Smith LE. Perianal mucinous adenocarcinoma: unusual case presentations and review of the literature. *Am Surg.* 2003;69(2):166-169.
94. Papagikos M, Crane CH, Skibber J, et al. Chemoradiation for adenocarcinoma of the anus. *Int J Radiat Oncol Biol Phys.* 2003;55(3):669-678.
95. Li LR, Wan DS, Pan ZZ, et al. Clinical features and treatment of 49 patients with anal canal adenocarcinoma. *Zhonghua Wei Chang Wai Ke Za Zhi = Chinese journal of gastrointestinal surgery.* 2006;9(5):402-404.
96. Pai VD, Jatal S, Engineer R, Ostwal V, Saklani AP. Multidisciplinary management of colorectal adenocarcinoma associated with anal fistula: an Indian series. *Colorectal Dis.* 2015;17(11):O240-O246.
97. Hongo K, Kazama S, Sunami E, Kitayama J, Watanabe T. Perianal adenocarcinoma associated with anal fistula: a report of 11 cases in a single institution focusing on treatment and literature review. *Hepatogastroenterology.* 2013;60(124):720-726.
98. Zalieckas JM. Treatment of perianal Crohn's disease. *Semin Pediatr Surg.* 2017;26(6):391-397.
99. Kelley KA, Kaur T, Tsikitis VL. Perianal Crohn's disease: challenges and solutions. *Clin Exp Gastroenterol.* 2017;10:39-46. Published 2017 Feb 8.
100. Strong SA. Perianal Crohn's disease. *Semin Pediatr Surg.* 2007;16(3):185-193.
101. Baumgart DC. The diagnosis and treatment of Crohn's disease and ulcerative colitis. *Dtsch Arztebl Int.* 2009;106(8):123-133.
102. Sulz MC, Burri E, Michetti P, et al. Treatment Algorithms for Crohn's Disease. *Digestion.* 2020;101 Suppl 1:43-57.
103. Weledji EP. Human immunodeficiency virus and the anorectum. *Alexandria J. Med.* 2013;49(2):163-167.

**FOR 3X FASTER RELIEF
FROM CONSTIPATION^{*,1,2}**

Cremaffin[®] Plus

Liquid Paraffin, Milk of Magnesia and Sodium Picosulphate Oral Emulsion



#PlusIsBetter



**OVERNIGHT
RELIEF^{3,4,5}**



**IMPROVES
STOOL FREQUENCY⁶**



**LUBRICATES &
SOFTENS HARD STOOL⁷**

^{*}As compared to onset of action of stool softeners like docusate. ^{**}Caution use in patients with impaired renal function. Currently no drug safety alerts on the Indian as well as worldwide health authority websites, Sep 2021. 1. Hannoodee S, Annamaraju P. Docusate. [Updated 2021 Jan 31]. In: StatPearls [Internet]. Treasure Island (FL): StatPearls Publishing; 2021 Jan-. Available from: <https://www.ncbi.nlm.nih.gov/books/NBK555942/> 2. Magnesium Hydroxide - Drugs.com [Internet]. Drugs.com. 2021 [cited 2 June 2021]. Available from: <https://www.drugs.com/ppa/magnesium-hydroxide.html> 3. Newton S, Hickey M and Brant J. Mosby's Oncology Nursing Advisor E-Book: A Comprehensive Guide to Clinical practice. 2nd edition. Elsevier publication; Pg no 290. 4. Sfetcu N. Health and drugs: Disease, prescription and medication. 2014 Laxatives 5. Susanne KH. et.al. Comparison of Bisacodyl and sodium picosulphate in the treatment of chronic constipation. Current Medical Research and Opinion. 2007;23(4):691-699 6. Patankar R. and Mishra A. A prospective non-comparative study to assess the effectiveness and safety of combination laxative therapy containing milk of magnesia, liquid paraffin and sodium picosulphate (Cremaffin-Plus[®]) in the management of constipation in patients with anal fissure/hemorrhoids/obstructive defecation syndrome. Int Surg J 2017;4:3899-906. 7. Portalatin M, Winstead N. Medical management of constipation. Clin Colon Rectal Surg 2012;25(1):12-19 8. Data on file. Liquid Paraffin, Milk of Magnesia & Sodium Picosulfate Oral emulsion, CREMAFFIN PLUS, COMPOSITION: Each 5 ml (1 teaspoonful approx.) contains: Liquid Paraffin I.P. 1.25 ml, Milk of Magnesia I.P. 3.75 ml, Sodium Picosulfate B.P. 3.33 mg. Colours: Carmoisine & Ponceau 4R, INDICATION: For the symptomatic relief of constipation in adults. DOSAGE AND ADMINISTRATION: Adults and children over 12 years: 7.5 ml (approx. 1½ teaspoonful) if the response is unsatisfactory, the dose may be increased to 15 ml (3 teaspoonful) or as advised by the physician. Children 5 to 12 years: 1 teaspoonful or as advised by the physician. Children 3 to 5 years, As advised by the physician. Children under 3 years. Not recommended Cremaffin Plus is best taken at bedtime preferably with water. Elderly: There is no need for dosage reduction in the elderly. CONTRAINDICATIONS: Patients with hypersensitivity to liquid paraffin, magnesium hydroxide or sodium picosulfate. Presence of intestinal obstruction, ileus, toxic megacolon gastric retention abdominal pain, nausea or vomiting, and in children under 3 years of age, patients with severely reduced renal function. WARNINGS AND PRECAUTIONS: In patients with renal impairment, Cardiac Arrhythmias, Colonic Mucosal Ulceration, Ischemic Colitis and Ulcerative Colitis, Use in Patients with Significant Gastrointestinal Disease. Prolonged use is not recommended. PREGNANCY AND LACTATION: The safety of Cremaffin Plus for use in pregnancy and lactation is not established. Therefore, as with other medicines, Cremaffin Plus should not be administered during pregnancy and lactation. ADVERSE REACTIONS: Liquid paraffin may cause anal seepage and irritation, granulomatous reactions. Nausea, headache, and vomiting are the most common adverse reactions (> 1%) reported with sodium Picosulfate and milk of magnesia. Abdominal pain, diarrhea, fecal incontinence, and proctalgia have been reported with sodium picosulfate. OVERDOSAGE: Gastric lavage may be performed where appropriate. Treatment should be symptomatic and supportive. Issued on: 5th Nov 2018 Source: Prepared based on full prescribing information version v3.0, dated: 29th Oct 2018 [®]Trademark of the Abbott Group of Companies. For full prescribing information, please contact: Medical Sciences Division, Abbott India Limited, Floor 17, Godrej BKC, Plot No. C - 68, BKC, Near MCA Club, Bandra (E), Mumbai - 400 051.

The Association of Colon and Rectal Surgeons of India

Contact Us



B/Gr. Floor, Salasar Classic,
Near Nagar Bhavan Hall, Fatak Road
Bhayander (West) Thane 401101



+91 93723 81974



secretary@acrsi.org

Supported by



Abbott